

25 pounds (5th percentile).  
32 inches (50th percentile).  
Temp - 99.6, Pulse - 100  
Resp - 26.  
Productive cough with thick, yellow-green sputum.  
Protruding abdomen.  
Large, foul smelling stools.

Sweat Chloride levels elevated.  
Fecal fat elevated.  
Trypsin in stool decreased.  
Chest X-ray shows atelectasis,  
infiltrations, and  
emphysemic changes.

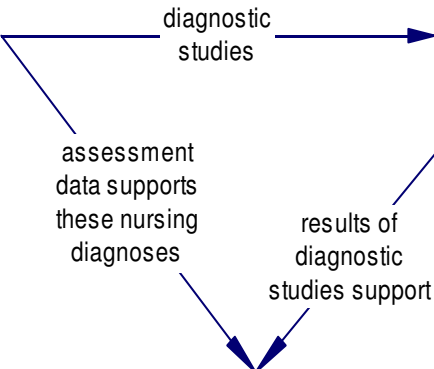
Constantly hungry yet  
underweight for age.  
Eats full meals and  
snacks between meals.

Kaitlyn has a cold,  
has lasted for 2 weeks  
and has not  
gotten better.

Normal birth weight.  
Full term vaginal delivery.  
Meconium ileus shortly  
after birth.



9 month -old, Kaitlyn, arrives in  
the clinic with "another cold."  
The mother states she thinks  
her daughter tastes salty when  
she kisses her. She has large,  
foul smelling stools.



1 Ineffective airway  
clearance r/t  
production of  
thick mucus.

For lots more on concept mapping visit  
<http://www.deanneblach.com> today!

goal

Improved ventilation and  
productive coughing and usual  
rate, rhythm, and depth of  
respiration using the  
diaphragmatic muscles.

Outcome met:  
Respirations < 22/min.  
Breath sounds improved.  
Tolerating chest PT.  
Expectorating yellow thick  
mucous.

nursing interven

Administer percussion and postural  
drainage every 4 hours.  
Auscultate lung sounds, reporting  
adventitious sounds.  
Monitor respiratory rate and rhythm.  
Encourage fluids with electrolytes.